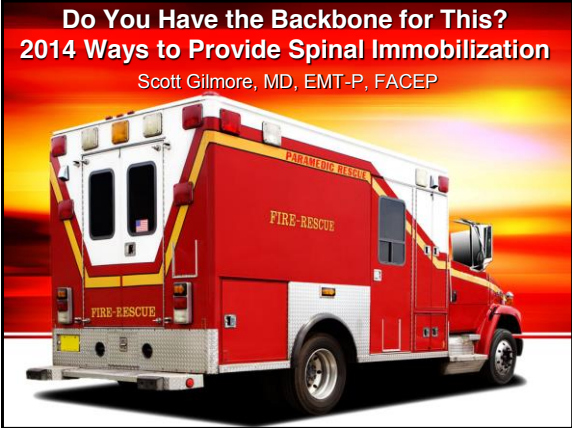


Do You Have the Backbone for This? 2014 Ways to Provide Spinal Immobilization

Scott Gilmore, MD, EMT-P, FACEP




Which Patient Need Spinal Immobilization?




History of Spinal Immobilization


- "A thorough search of the literature, however, **reveals few references** to motor vehicle accidents in terms of the environment that is present immediately after the accident, or in terms of the position of the victim in relationship to the various types of injuries, and **no reference whatever** that might deal with specific treatment techniques at the accident site."
- "Emergency room personnel accept these patients without questioning whether their injuries are those sustained in the accident, or **whether the injuries may have been compounded by the actions incident to the victim's removal from the wreck and transportation to the hospital.**"



Kossuth LC. The removal of injured personnel from wrecked vehicles. J Trauma 1965, 5:703-8.

History of Spinal Immobilization

- Case series of 958 patients who suffered spinal cord injury over 25 years.
- Delayed onset of paralysis (hours or days)
- "Failure to recognize the injury ...and to protect the patient from consequences of his unstable spine"
- "It may have occurred when the patient was being moved from the site of the accident to a hospital. **Quite frequently it occurred following admission to hospital.**"
- "The importance of proper first aid was deduced from the fact that 29 patients developed further paralysis through faulty handling."



Geisler WO, Wynne-Jones M, Jousse AT. Early management of the patient with trauma to the spinal cord. Med Serv J Can. 1966, 22:512-23.

History of Spinal Immobilization





Fig. 17. Grasping ejected victim's clothing, rescuers turn him part way, position board, turn him back on it.

Fig. 18. After straps carried in every rescue vehicle assure patient's security, he is ready for journey to hospital.



Farrington JD. Death in a ditch. Bull Am Coll Surg 1967, 52: 121-130.


What are We Trying to Prevent?

- Aggravation of an existing axial spine injury that could
 - Cause a spinal cord injury
 - Worsen a spinal cord injury




The Magnitude of the Problem


- 3-25% of spinal cord injuries are secondary
 - Occurring during prehospital or early hospital care
 - Result of inappropriate management
 - Lack of spinal immobilization



Sundström T, Asbjørnsen H, Habiba S, Sunde GA, Wester K. Prehospital use of cervical collars in trauma patients: a critical review. J Neurotrauma 2014, 31: 531-540.

But Wait


- Identifying a neurological decline
- Extrapolating results to the prehospital setting
- Age of studies
- Approximately 5% of patients with spinal injuries experience some degree of neurological worsening even with good immobilization of spine.



Sundström T, Asbjørnsen H, Habiba S, Sunde GA, Wester K. Prehospital use of cervical collars in trauma patients: a critical review. J Neurotrauma 2014, 31: 531-540.

Spinal Immobilization

- 12 of 186 patients with ASIA Grade A (6.0%) complete spinal cord injury had neurological deterioration during the first 30 days
 - No patients with penetrating trauma had deterioration
 - Early deterioration (less than 24 hours) was related to traction and immobilization
 - Delayed deterioration (between 24 hours and 7 days) was related to sustain hypotension
 - Late deterioration (more than 7 days) was related to vertebral artery injury




Harrop JS, Sharan AD, Vaccaro AR, Przybylski GJ. The cause of neurologic deterioration after acute cervical spinal cord injury. Spine (Phila Pa 1976) 2001, 26(4): 340-6.

Spinal Immobilization


- Pros
 - Spinal column injuries will not be aggravated, preventing additional spinal cord injury

- Cons
 - Airway compromise
 - Respiratory compromise
 - Aspiration risk
 - Increased intracranial pressure
 - Cutaneous pressure ulcers
 - Iatrogenic pain
 - Increased difficulty in patient handling
 - Combativeness/resistance
 - Increased cost
 - Delay to definitive care



Airway Compromise


- Endotracheal intubation significantly more difficult in patients with immobilization
 - 41% failure rate
 - Significant rate of reintubation in the ED for unrecognized EMS endotracheal tube malposition or dislodgement



Kaups KL, Davis JW. Patients with gunshot wounds do not require cervical spine immobilization and evaluation. J Trauma. 1998;44:865-867.

Airway Compromise

- Use of hard collar, straps and sandbags reduces view for laryngoscopy
 - View improved by 1 grade in 56% of patients with manual in-line stabilization (MILS)
 - View improved by 2 grades in 10% of patients with MILS
- MILS impedes endotracheal intubation
 - 50% intubation failure after 30 seconds
 - 5.7% intubation failure in those without stabilization
- MILS doubles force applied during intubation



Abram S, Bulstrode C. Routine spinal immobilization in trauma patients: what are the advantages and disadvantages? Surgeon. 2010; 8:218-222.

Respiratory Compromise

- Straps tightened across the torso have a restrictive effect
 - Lowers forced vital capacity (13.97%)
 - Lowers forced expiratory volume over 1 second (14.16%)
 - Lowers forced mid-expiratory flow (18.70%)
- Injuries to the chest wall and lungs further interfere with respiratory mechanics



Totten VY, Sugarman DB. Respiratory effects of spinal immobilization. Prehosp Emerg Care. 1999;3:347-352.

Increased Aspiration Risk

- Mouth opening compromised by cervical collar
- Supine position
- Easier aspiration



Increased Intracranial Pressure

- A collar may increase intracranial pressure by 5.3 mmHg ($51.6 \pm 60.6\%$)
 - Obstruction of venous drainage → edema
 - Persistent painful stimulus from collar pressure points
- Venous congestion by collars exacerbate global brain injuries
 - Observed after attempted suicide by hanging
- 25% of patients with spinal injury have at least a mild TBI



Mobbs RJ, Stoodley MA, Fuller J. Effect of cervical hard collar on intracranial pressure after head injury. ANZ J Surg 2002; 72: 389-391.

Cutaneous Pressure Ulcers

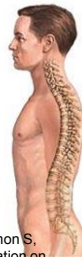- Contact pressure in the occipital and sacral region are above the pressures at which tissue necrosis and pressure ulcers develop
 - Significant hypoxia in sacral tissue of healthy adults after 30 minutes on spine board
 - Early pressure ulcer development begins prior to arrival at the hospital



Ham W, Schoonhoven L, Schuurmans MJ, Leenen LPH. Pressure ulcers from spinal immobilization in trauma patients: a systematic review. J Trauma Acute Care Surg 2014, 76:1131-1141.

Iatrogenic Pain

- Pain in the lower back and cervical spine due to the anatomically incorrect positioning caused by a flat backboard
- Exacerbation of existing painful conditions
- New pain to develop in areas not painful prior to the application of the spine board
 - In 21 uninjured adults, 55% developed moderate to severe pain after being immobilized for 30 minutes
 - In healthy volunteers, lower back and cervical pain reported to persist for 24 hours after being subject to only one hour on a spine board



Chan D, Goldberg R, Tascone A, Harmon S, Chan L. The effect of spinal immobilization on healthy volunteers. Ann Emerg Med. 1994;23:48-51.

Increased Cost

- Difficult to distinguish between pain caused by trauma and pain caused by the spine board
 - Increased number of imaging studies
 - Increased cost of evaluation
- Unnecessary radiological studies have been correlated with increasing risk for the development of cancer



Delay to Definitive Care

- Time required to properly immobilize a cervical spine is not short
 - Experienced emergency medical technicians require 5.6 minutes (± 1.49)
- Can be catastrophic for a patient with penetrating trauma requiring urgent surgical intervention for airway compromise or hemorrhage



Stuke LE, Pons PT, Guy JS, Chapleau WP, Butler FK, McSwain NE. Prehospital spine immobilization for penetrating trauma – review and recommendations from the Prehospital Trauma Life Support executive committee. J Trauma. 2011, 71; 763-770.

Penetrating Trauma

- No study has demonstrated that penetrating trauma can produce an unstable spine injury
- Progression of spinal cord injury has not been demonstrated to occur following penetrating trauma
- Immediate and permanent neurologic deficit
- An analysis of the National Trauma Data Bank noted a two fold increase in mortality in patients who were immobilized compared to similar patient who were not.



Haut ER, Kalish BA, Efron DT, Haider AH, Stevens KA, Kieninger AN, Cornwell EE, Chang DC. Spine immobilization in penetrating trauma: more harm than good? J Trauma 2010;68;115-121.

POSITION STATEMENT

EMS SPINAL PRECAUTIONS AND THE USE OF THE LONG BACKBOARD
 National Association of EMS Physicians and American College of Surgeons Committee on Trauma



Available online at www.naemsp.org

Questions?

Thank you



gilmorew@wustl.edu

